

Localised Cryptococcal Scalp Osteomyelitis in an Immunocompetent Man- A Rare Case

SREENATH K, SANJEEB SHARMA, TH GOJENDRA SINGH, KH GOJEN SINGH, KHURAIJAM RANJANA DEVI

ABSTRACT

Cryptococcosis is one of the commonly associated opportunistic fungal infection in patients with AIDS, caused mostly by *Cryptococcus neoformans*. Lung and the central nervous system are the most common sites affected. Osseous involvement occurs in 5-10% of patients with disseminated *Cryptococcus*. Although extremely rare, sometimes it can present as isolated cryptococcal osteomyelitis in HIV-negative patients. Here we present a case report of seventy two year old healthy male with

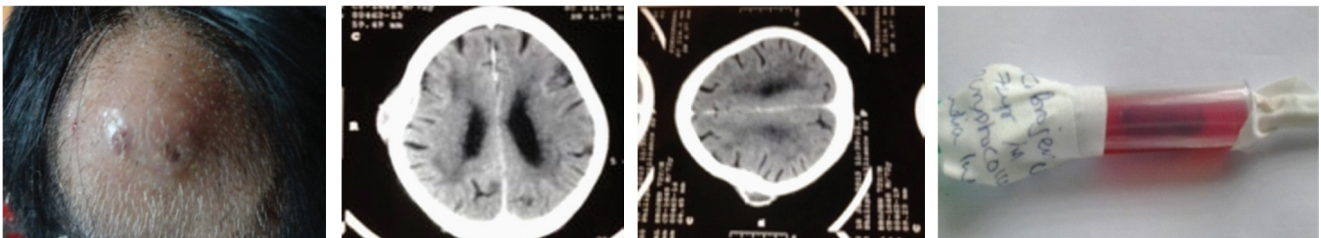
isolated swelling of parietal bone on right side of scalp who is HIV negative with prior history of completely cured pulmonary tuberculosis. The patient was treated with fluconazole and repeated aspirations were performed. He was cured completely after three months of treatment. Even though isolated cryptococcal osteomyelitis of the parietal bone of scalp in HIV-negative is extremely rare, it should be considered in the relevant differential diagnosis of any localized swelling of scalp since it can be cured completely.

Keywords: Antifungal, Cryptococcal, Immunocompetent, Osteomyelitis

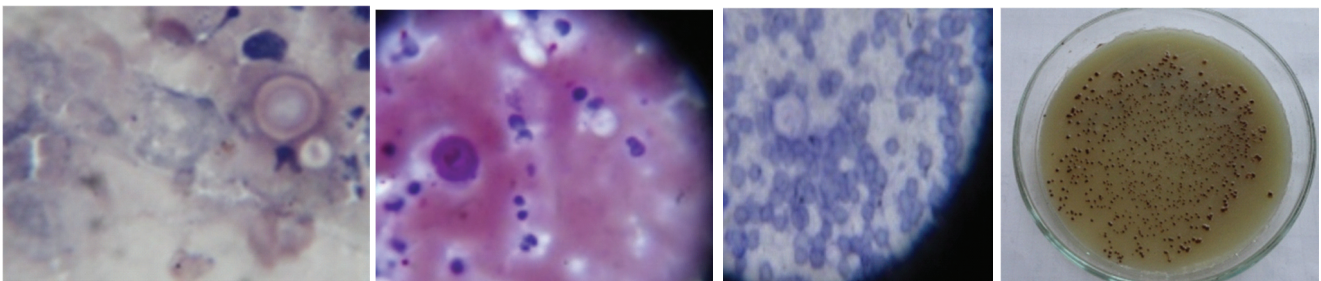
CASE REPORT

A seventy two year old male presented to the surgery outpatient department of Regional institute of medical sciences, Imphal with chief complaint of swelling over the right side of scalp for one months [Table/Fig-1]. Initially started as a small swelling, which gradually increased in size and reached the present size. The swelling was occasionally associated with mild pain. No history of trauma, seizure, headache, focal neurological deficits, altered behavior or any other history suggestive of central nervous system involvement. There was no other major complaints suggestive of pulmonary, cardiovascular, gastrointestinal, or genitourinary systems involvement. Patient is neither hypertensive nor diabetic. One year back he was treated for pulmonary tuberculosis. He was declared as cured after six months of antitubercular treatment. There is no other significant past history. On local examination there is a 3*3 cms sized, cystic, translucent, nontender, non pulsatile swelling over the right side of scalp. Detailed general and systemic examination was performed. Initially, FNAC of swelling and skull X-ray was advised. Skull X-ray showed lytic lesion in the right side of scalp bone. FNAC revealed degenerated neutrophils and numerous capsulated budding yeast cells morphologically resembling cryptococcal species. Cryptococcal abscess of parietal bone was suspected. Antifungal treatment started with Tb. Fluconazole 400mg once daily. Further investigations were planned. Complete haemogram was normal apart from raised ESR levels (100mm/1 hr). Liver function tests, renal function tests

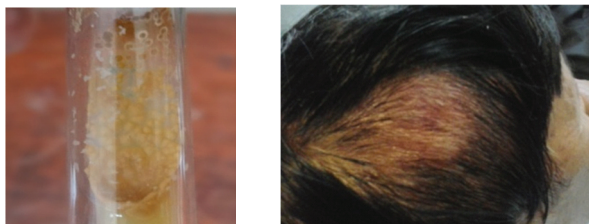
chest X-ray were within normal limits. HIV testing for type 1 and 2 were non reactive as well as negative for hepatitis B and C. CT scan of head showed focal bony lytic lesion involving full thickness of right parietal bone with rim enhancing hypodense collection in the adjacent subcutaneous tissue and epidural space suggestive of osteomyelitis [Table/Fig-2,3]. Aspiration with wide bore needle was done and specimen [Table/Fig-4] sent for microbiological analysis. Routine bacteriological culture report was negative. India ink preparation, Geimsa staining, Meyer's mucicarmine staining, PAS staining showed *Cryptococcus* morphology (capsulated budding yeast cells) [Table/Fig-5-7]. The CALAS test (Cryptococcal Antigen latex Agglutination System, Meridian diagnostics, Cincinnati, Ohio) for *Cryptococcus* was positive with a serum titre of 1:100. Specimen was sent for fungal culture and report came as positive for *cryptococcus* after 2 wks of incubation. Fungal culture of the aspirate on Sabouraud's dextrose agar and Bird seed Agar showed growth of brown pigmented colonies of *Cryptococcus neoformans* due to melanin production [Table/Fig-8,9]. The fungal isolates obtained were further confirmed by positive urease test, positive inositol assimilation test and the growth on L-Canavanine glycine bromothymol blue (CGB) agar. Sputum, urine and blood were collected and subjected to india ink preparation and fungal culture which was turned out to be negative for cryptococcal species. Antifungal susceptibility testing was done by disc diffusion method for Amphotericin B (20µg), fluconazole (25µg) and voriconazole (1µg) using reference for *Cryptococcus* species as given in



[Table/Fig-1]: Cryptococcal osteomyelitis of the scalp during initial presentation **[Table/Fig-2]:** CT scan of head showing focal bony lytic lesion involving full thickness of right parietal bone **[Table/Fig-3]:** CT scan of head showing focal bony lytic lesion involving full thickness of right parietal bone **[Table/Fig-4]:** Aspirated sample from the swelling



[Table/Fig-5]: PAS staining shows PAS positive capsulated budding yeast form of *Cryptococcus* from the aspirated material **[Table/Fig-6]:** Mayer's mucicarmine staining of aspirated material showing budding yeast cells demonstrating capsule of *Cryptococcus spp* **[Table/Fig-7]:** Giemsa stain of the aspirated material showing capsulated budding yeast cells **[Table/Fig-8]:** Growth of *Cryptococcus* in Bird seed agar showing colonies with brown pigmentation due to melanin production



[Table/Fig-9]: Growth of *Cryptococcus* in Sabourds dextrose agar showing brown pigmented colonies **[Table/Fig-10]:** After 2 weeks of treatment

CLSI M44A guideline. It was sensitive to Amphotericin B, fluconazole as well as for voriconazole. Repeated aspirations were performed with proper dressing. Anti fungal therapy with fluconazole continued. Patient responded well with treatment [Table/Fig-10]. Size of swelling completely reduced after one month of treatment. Fluconazole was continued for 3 months and stopped after that.

DISCUSSION

Cryptococcus neoformans is an encapsulated heterobasidiomycetous fungus which crosses the entire spectrum of patient populations, from the apparently immunocompetent host without an underlying disease to those severely immunocompromised from infection with the human immunodeficiency virus (HIV), an organ transplantation, or a malignancy [1]. It has a wide range of clinical presentations, which can vary from asymptomatic colonization of the respiratory airways to dissemination of infection into any part

of the human body [1,2]. Cryptococcal osteomyelitis usually occurs as part of a disseminated cryptococcal infection [2]. Osseous involvement occurs in 5-10% of patients with disseminated *Cryptococcus* [3]. Isolated cryptococcal osteomyelitis is very rare and more so in immunocompetent patients [2-4]. Of all cryptococcal infections, 10-40% of patients have no apparent immune deficiency [5]. Disseminated disease may occur in up to 62% of HIV- seronegative patients with cryptococcosis; however, cryptococcal osteomyelitis is rare [5]. Seventy-five percent of cases involved only one single site of bone infection, with vertebrae being the most common site. Scalp osteomyelitis is extremely rare [6]. Sarcoidosis is the most common underlying disease, followed by tuberculosis and previous steroid therapy [6]. Till 2005 only 47 cases of isolated cryptococcal osteomyelitis have been reported in HIV-negative patients [7]. Cryptococcal osteomyelitis usually present with swelling and pain of the soft tissue surrounding the bone that may or may not be tender which is usually not associated with erythema or sinus formation but with mild elevation of local temperature. Radiologic examination reveals a lytic lesion with mild or absent periosteal reaction [8]. As per the Infectious Diseases Society of America (IDSA) 2010 guidelines non-meningeal, non-pulmonary cryptococcosis with infection limited to a single site can be successfully treated with fluconazole (400 mg [6 mg/kg] per day orally) for six to twelve months [9]. Previous study have shown that single site cryptococcal osteomyelitis can be completely cured after ten weeks of fluconazole at a dose of 200 mg/day [10]. In our case, the patient was completely cured with oral fluconazole 400 mg for a period of three months.

CONCLUSION

Isolated cryptococcal osteomyelitis of the parietal bone of the scalp in HIV-negative immunocompetent patient is a rarest among the rare clinical manifestations of cryptococcosis. Even though extremely rare it should be considered in the relevant differential diagnosis of any localised swelling of scalp.

REFERENCES

- [1] Perfect JR. Cryptococcosis. *Infect Dis Clin North Am.* 2002 ; 16(4): 837-74.
- [2] Subramanian S, Mathai D. Clinical manifestations and management of cryptococcal infection. *J Postgrad Med.*2005; 51 Suppl 1: S21-26.
- [3] Behrman RE, Masci JR, Nicholas P. Cryptococcal skeletal infections: case report and review. *Rev Infect Dis.* 1990; 12:181-90.
- [4] Al-Tawfiq JA, Ghandour J. *Cryptococcus neoformans* abscess and osteomyelitis in an immunocompetent patient with tuberculous lymphadenitis. *Infection.* 2007; 35: 377-82.
- [5] Karmakar P, Jeyarajah R, Ramasubramanian V. Isolated cryptococcal osteomyelitis in immunocompetent patient. *J Indian Med Assoc.* 2011; 109(8):592-94.
- [6] Liu PY. Cryptococcal osteomyelitis: case report and review. *Diagn Microbiol Infect Dis.* 1998; 30:33-5.
- [7] Irfan Qadir , Farheen Ali, Umair Z. Malik, Masood Umer . Isolated cryptococcal osteomyelitis in an immunocompetent patient. *J Infect Dev Ctries.* 2011; 5(9):669-73.
- [8] Raftopoulos I, Meller JL, Harris V, Reyes HM. Cryptococcal rib osteomyelitis in a pediatric patient. *J Pediatr Surg.*1998; 33: 771-3.
- [9] Perfect JR et al. Clinical practice guidelines for the management of cryptococcal disease: 2010 update by the Infectious Diseases Society of America. *Clin Infect Dis.*2010; 50: 291-322.
- [10] Murphy SN, Parnell N. Fluconazole treatment of cryptococcal rib osteomyelitis in an HIV-negative man. A case report and review of the literature. *J Infect.* 2005; 51(5): 309- 11.

AUTHOR(S):

1. Dr. Sreenath K
2. Dr. Sanjeeb Sharma
3. Dr. Th Gojendra Singh
4. Dr. Kh Gojen Singh
5. Dr. Khurajam Ranjana Devi

PARTICULARS OF CONTRIBUTORS:

1. Junior Resident, Department of Surgery, Regional Institute of Medical Sciences, Imphal, India.
2. Junior Resident, Department of Microbiology, Regional Institute of Medical Sciences, Imphal, India.
3. Assistant Professor, Department of Neurosurgery, Regional Institute of Medical Sciences, Imphal, India.
4. Assistant Professor, Department of Surgery, Regional Institute of Medical Sciences, Imphal, India.

5. Associate Professor Department of Microbiology, Regional Institute of Medical Sciences, Imphal, India.

NAME, ADDRESS, E-MAIL ID OF THE CORRESPONDING AUTHOR:

Dr. Th Gojendra Singh,
Assistant Professor Neurosurgery Unit, Department of Surgery, RIMS Imphal, Manipur- 795004, India.
Phone : 9615839541, E-mail: gojendraneuro@gmail.com

FINANCIAL OR OTHER COMPETING INTERESTS:

None.

Date of Publishing: Dec, 01 2014